

Module 6 LO1

Pectoral Girdle

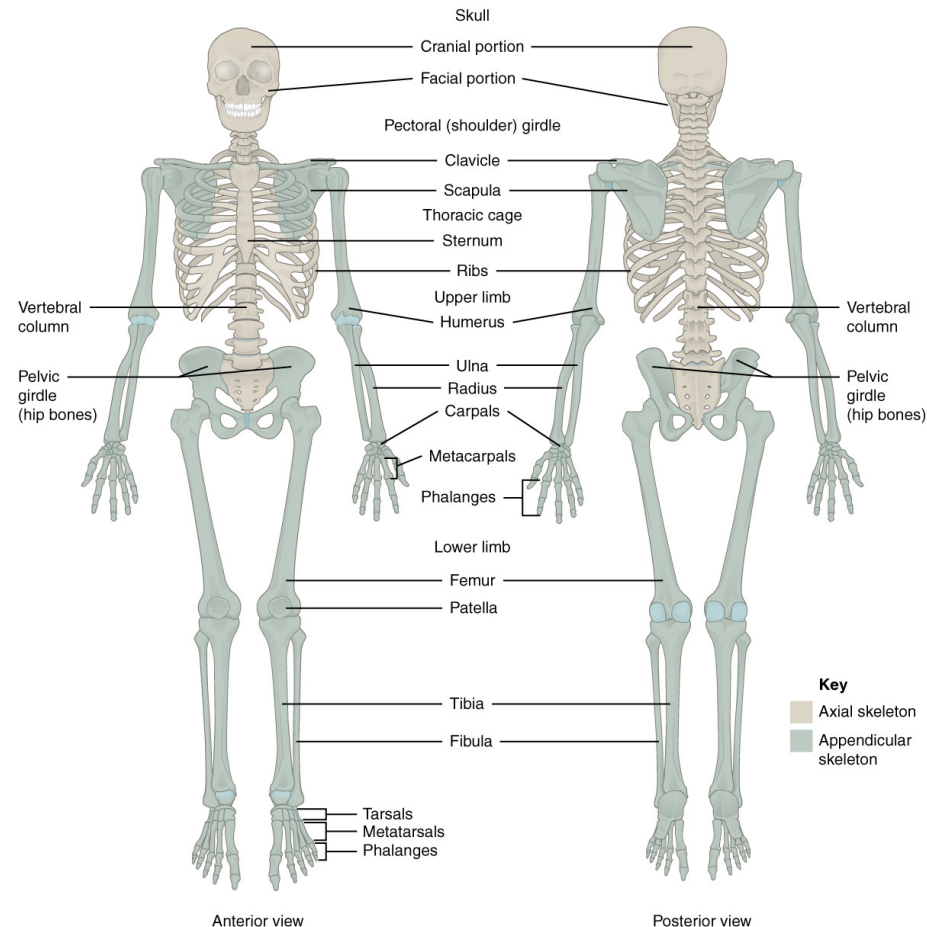
Dr. Lisa Brinn

lbrinn@fiu.edu

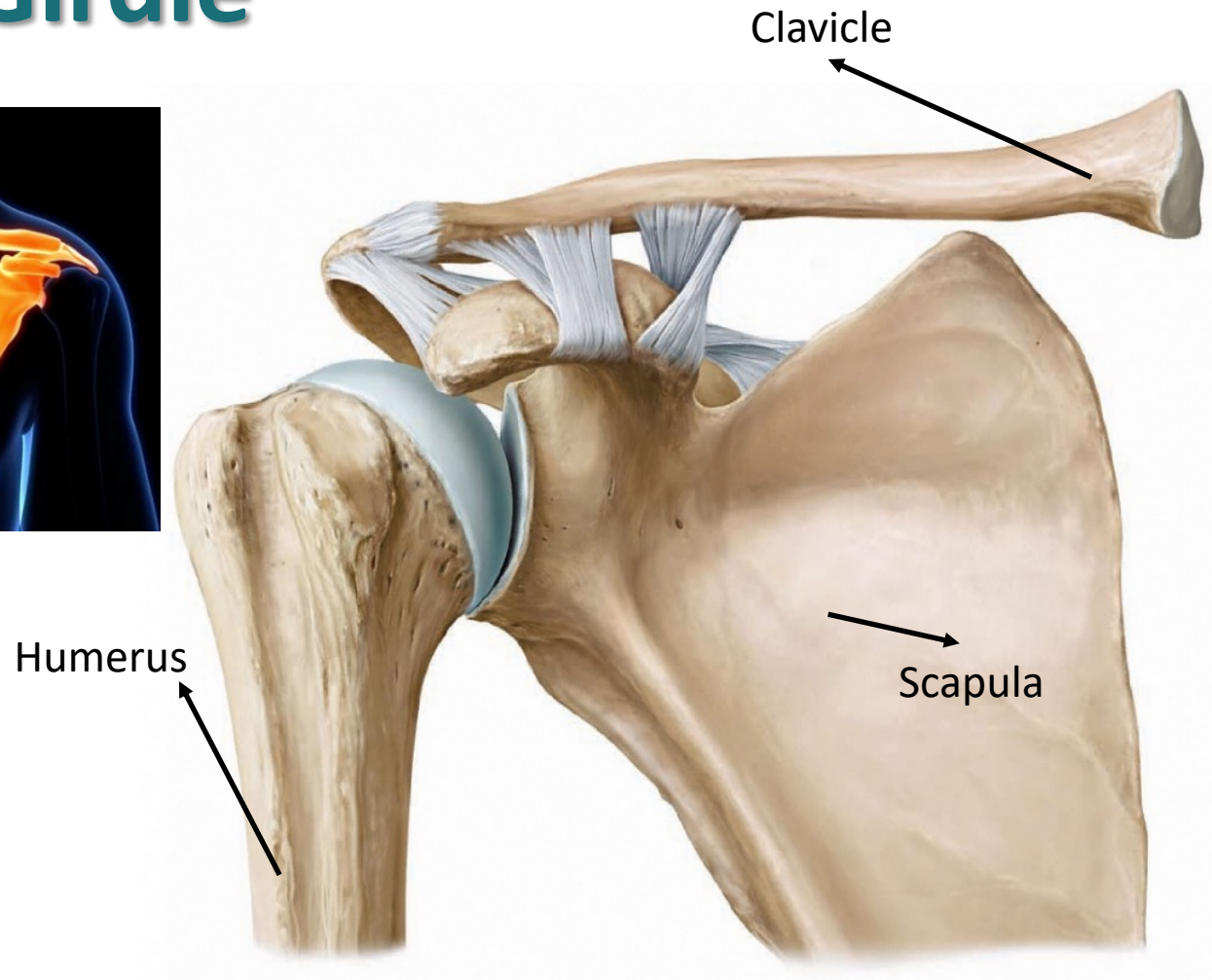
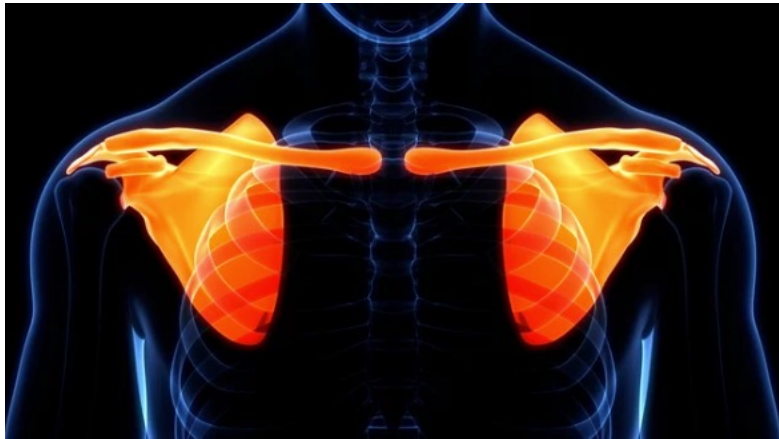[Link for video recording](#)

Appendicular Skeleton

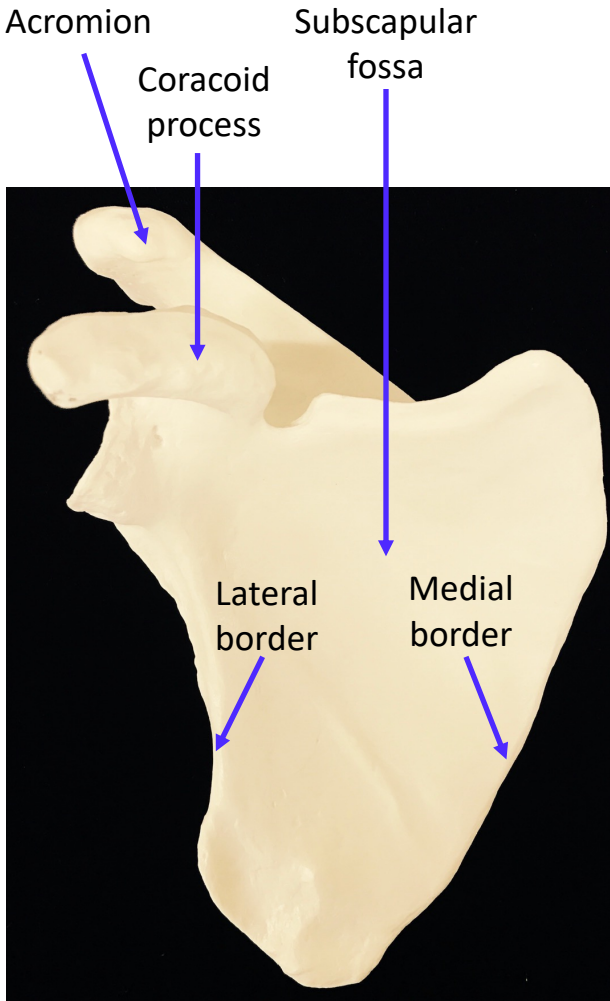
- Its primary function is movement
- It includes bones of the upper and lower limbs
- Girdles attach the limbs to the axial skeleton



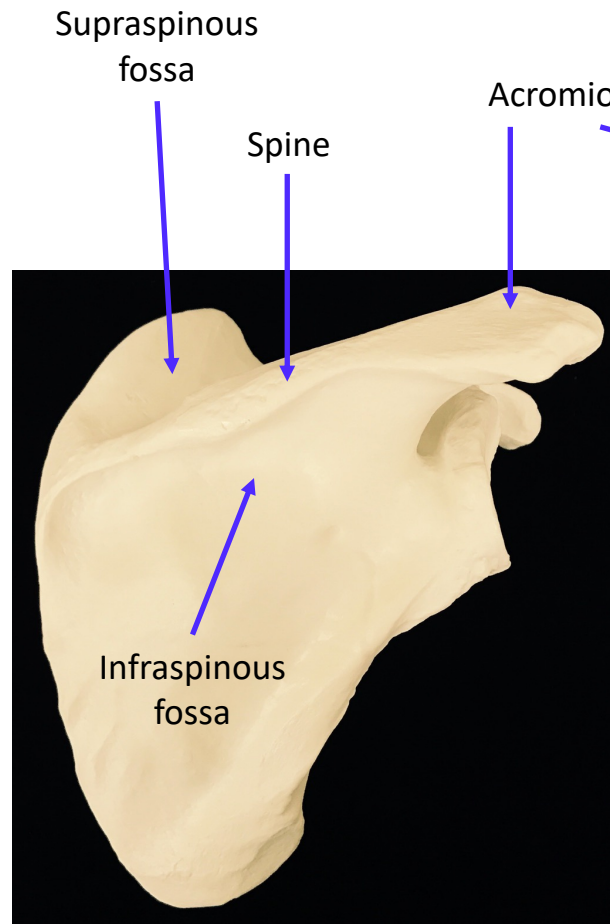
1. Pectoral Girdle



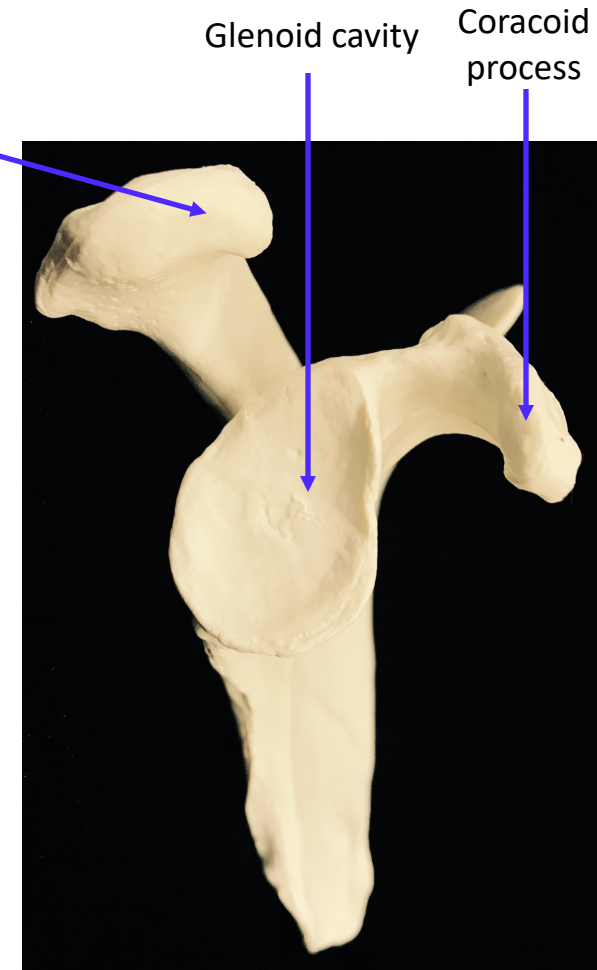
Scapula



ANTERIOR

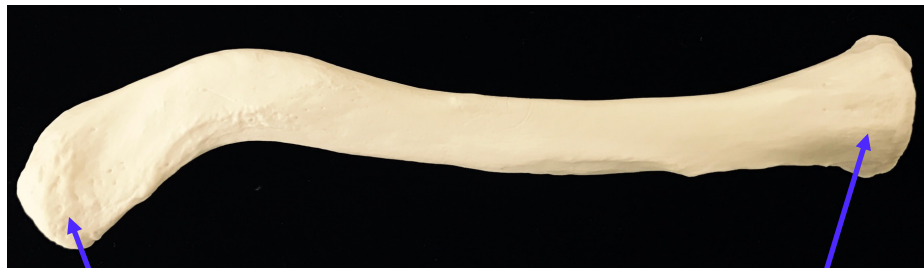

POSTERIOR



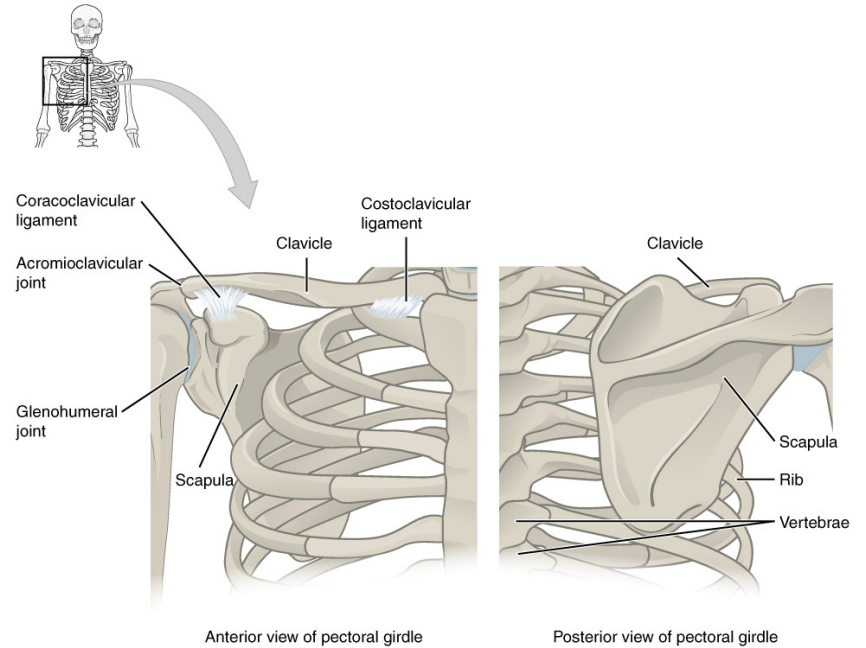
MEDIAL

Clavicle



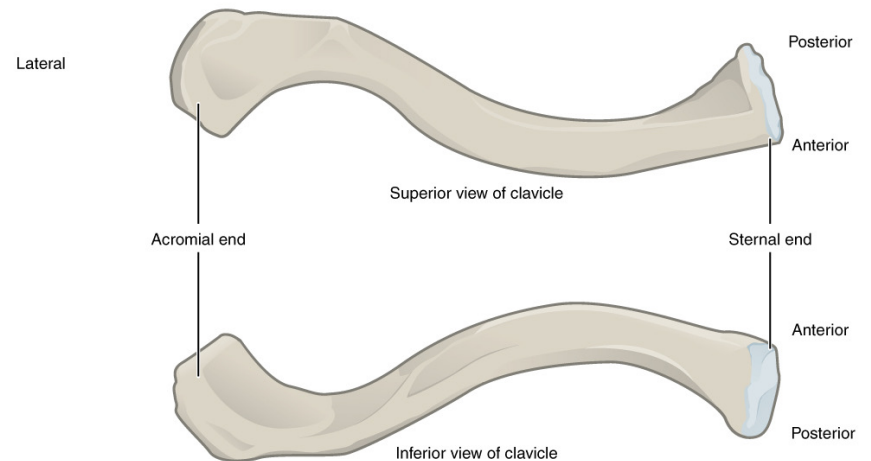
Acromial end

Sternal end



Anterior view of pectoral girdle

Posterior view of pectoral girdle

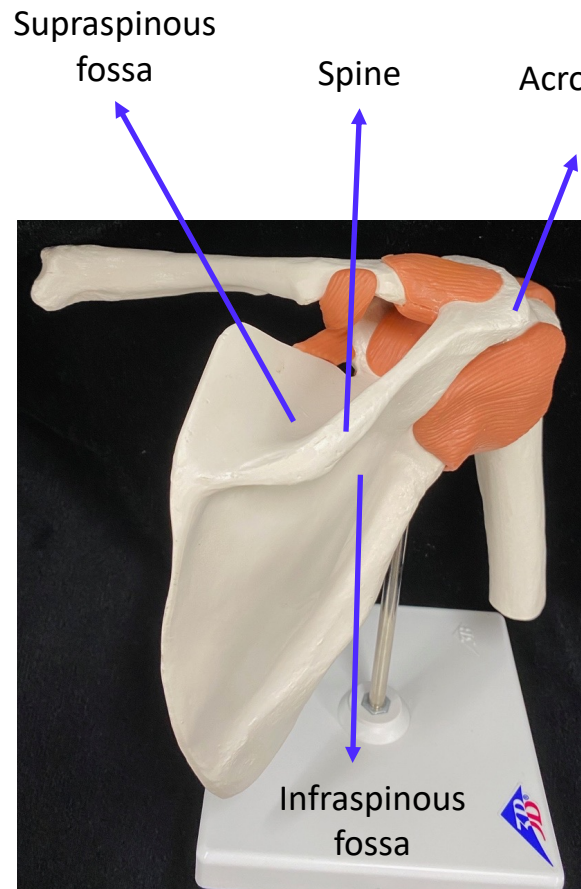


Superior view of clavicle

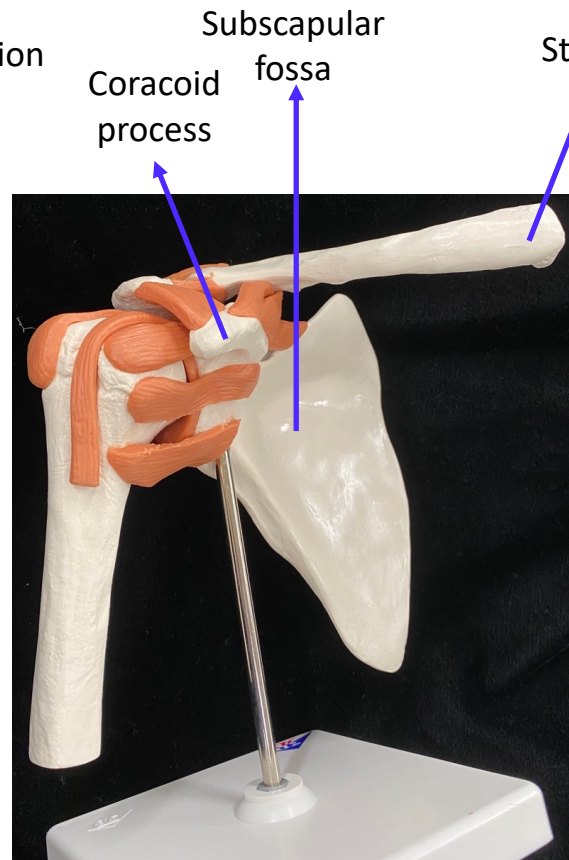
Inferior view of clavicle

SUPERIOR

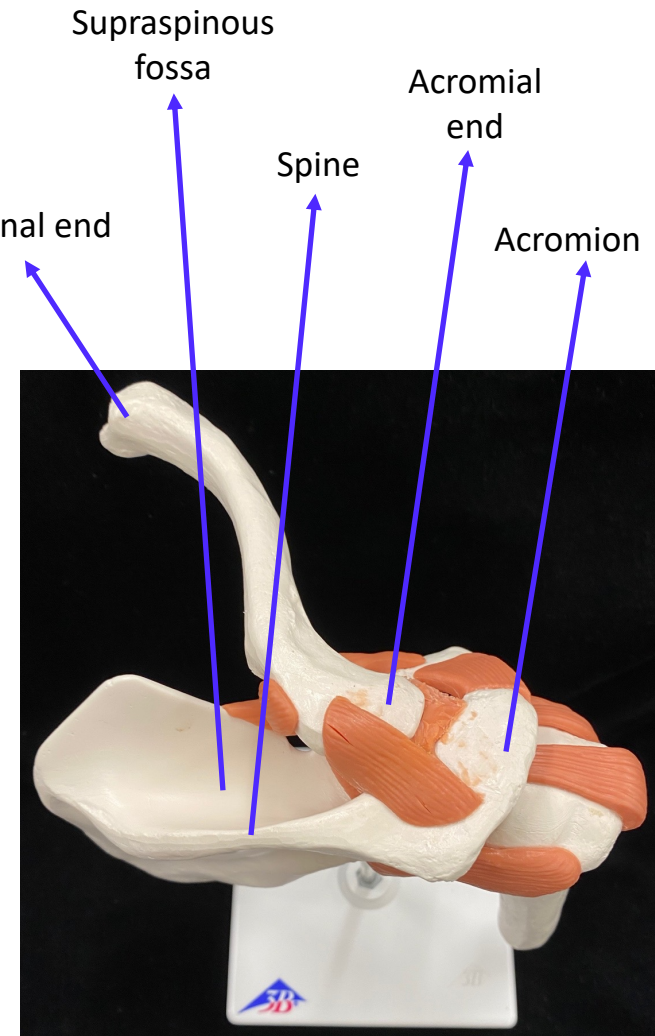
Pectoral Girdle



SUPEROMEDIAL



ANTEROMEDIAL



SUPERIOR